

Yertleuova B., PhD, acting associate professor, **the main author**, <https://orcid.org/0000-0003-1990-570X>

Non-profit JSC Zhangir Khan West Kazakhstan Agrarian Technical University, Institute of Veterinary Medicine and Agrotechnology, Zhangir Khan 51, Uralsk, Republic of Kazakhstan, aliba.87@mail.ru

Ichshanova A., PhD, acting associate professor, <https://orcid.org/0000-0002-7344-5479>

Non-profit JSC Zhangir Khan West Kazakhstan Agrarian Technical University, Institute of Veterinary Medicine and Agrotechnology, Zhangir Khan 51, Uralsk, Republic of Kazakhstan, aiman_86is@mail.ru

Kozhayeva A., Doctor PhD, <https://orcid.org/0000-0003-4994-5737>

Non-profit JSC « Shakarim University of Semey» st. Glinka, 20A, Semey, Republic of Kazakhstan aigerim.kozhayeva@mail.ru

Sidikhov B., PhD, associate professor, <https://orcid.org/0000-0001-6471-3737>

Non-profit JSC Zhangir Khan West Kazakhstan Agrarian Technical University, Institute of Veterinary Medicine and Agrotechnology, Zhangir Khan STR., 51, Uralsk, Republic of Kazakhstan, sidihovbm@mail.ru

Gabdullin D., PhD, acting associate professor, <https://orcid.org/0000-0002-6523-1905>

Non-profit JSC Zhangir Khan West Kazakhstan Agrarian Technical University, Institute of Veterinary Medicine and Agrotechnology, Zhangir Khan 51, Uralsk, Republic of Kazakhstan, dosya_gabdullin@mail.ru

Montayeva N., PhD, associate professor, <https://orcid.org/0000-0003-2614-1592>

Non-profit JSC Zhangir Khan West Kazakhstan Agrarian Technical University, Institute of Veterinary Medicine and Agrotechnology, Zhangir Khan 51, Uralsk, Republic of Kazakhstan, montayeva-n@mail.ru

Usenov Zh., PhD, acting associate professor, <https://orcid.org/0000-0002-2100-1948>

Non-profit JSC Zhangir Khan West Kazakhstan Agrarian Technical University, Institute of Veterinary Medicine and Agrotechnology, Zhangir Khan 51, Uralsk, Republic of Kazakhstan, usenov79@mail.ru

THE EFFECT OF AN *ARTEMISIA LERCHIANA* - BASED OINTMENT ON THE HEALING PROCESS OF ASEPTIC WOUNDS IN CATS

ANNOTATION

This study evaluated the effectiveness of a 10% ointment containing *Artemisia lerchiana* essential oil in promoting the healing of aseptic postoperative wounds in domestic cats. Two groups of ten cats each underwent ovariohysterectomy and received different postoperative treatments: the experimental group was treated with the *Artemisia lerchiana* ointment, while the control group received the classical wound treatment using Vishnevsky liniment.

Over a 10-day observation period, wound healing progress, physiological indicators (body temperature, heart rate, respiratory rate), and hematological parameters were assessed. The experimental group demonstrated faster wound epithelialization, reduced inflammation, minimal swelling, and better overall physiological stability compared to the control group. Hematological analysis revealed more balanced recovery parameters, with lower leukocyte and platelet counts, indicating decreased inflammatory and coagulation activity. The control group showed slower healing, increased inflammatory response, and more pronounced signs of discomfort.

The results indicate that the 10% *Artemisia lerchiana* ointment effectively promotes tissue regeneration and modulates the inflammatory process. Therefore, this phytotherapeutic agent is recommended as a safe and effective treatment for aseptic postoperative wounds in cats, with potential for broader veterinary applications.

Key words: *Artemisia lerchiana*, cats, aseptic wound, granulation, epithelialization.

Introduction. Local treatment of wounds with medicinal preparations is distinguished by its simplicity, accessibility, and economic efficiency. Currently, the search for drugs that have anti-inflammatory effects, promote regenerative processes, and cause minimal side effects is highly relevant. This is especially important in chronic diseases, as phytotherapy and phytoprophylaxis are carried out over long periods [1,2].

Indications for using such agents include hard-to-heal wounds, trophic ulcers, burns, and pressure sores. The primary goal of prescribing these drugs is to stimulate the regeneration of dermal and connective tissues in the damaged area.

One of the pressing issues in veterinary surgery today is wound healing. This problem is directly associated with the prevalence of ulcers of various etiologies, frequent purulent complications, and significant treatment costs [3-7].

There are many methods for treating wounds, including newly developed and introduced modern approaches. However, excessive and widespread use of antibacterial drugs leads to decreased sensitivity or complete resistance of the microflora to these medications [8-10].

In such cases, medicinal plants with antimicrobial properties, as well as those that promote wound healing, considered as alternatives to traditional antibiotics, represent a promising direction. Among them, plants belonging to the genus *Artemisia* deserve special attention.

Most plants of the *Artemisia* genus are medicinal plants. In recent years, research on the essential oils and extracts of wormwood has attracted particular interest due to their antibacterial, antiviral, anti-inflammatory, nematocidal, and fungicidal properties [11-16].

Among the metabolites of *Artemisia* species, terpenoids have been the most extensively studied. One of the promising directions for treating inflammatory diseases is the topical application of plant essential oils [17-19].

Studies by L. P. Tsedenova and other authors have shown that some components of the essential oil of *Artemisia lerchiana* (1,8-cineole, borneol, α -thujone, borneyl acetate) protect the body from pathogens and exhibit fungicidal and bactericidal activity. Cineole and borneol in *A. lerchiana* are active substances with bactericidal and antimicrobial properties [20].

Research on the antimicrobial activity of wormwood tinctures revealed that two species – *Artemisia absinthium* and *Artemisia lerchiana*–showed significant antimicrobial effects against test microorganisms. Specifically, these tinctures demonstrated notable activity against *Staphylococcus aureus*, *Streptococcus*, and *Escherichia coli* [20,21].

The main representatives of the conditional pathogenic microflora found in wounds of dogs and cats include *Staphylococcus* species (both coagulase-positive and coagulase-negative), purulent and epidermal *Streptococcus* species, and, less frequently, *Escherichia coli*. In our studies, gram-positive bacteria (*Staphylococcus*) were detected in 83% of wounds, and gram-negative bacteria (*Escherichia coli*) in 50% of wounds in dogs and cats [22].

Therefore, the primary aim of our research was to prepare an ointment (a fatty base medicinal form) based on 10% *Artemisia lerchiana* ointment and to study its wound-healing effects on animals.

Materials and methods. The clinical part of the study was conducted between November 2024 and May 2025 at the «Zhardem-Vet» veterinary outpatient clinic affiliated with the Zhangir Khan West Kazakhstan Agrarian-Technical University. The study involved 20 domestic cats aged 10–12 months, weighing between 2.0 and 2.5 kg, which were brought in for ovariohysterectomy. All experimental procedures involving animals were carried out in accordance with the «Rules for the Use of Experimental Animals».

Surgical operations were performed under general anesthesia, adhering to the principles of humane treatment of animals, as well as the sanitary regulations (No. 1045-73) related to the equipment, placement, and maintenance of experimental biological facilities (vivaria).

The overall study design is presented in Table 1.

Table 1 – Study design for healing of aseptic wounds in domestic cats

Study groups (n)	Animal species	Investigated medication	Research direction
Group №1 (Experimental group), n = 10	cats	10% <i>Artemisia lerchiana</i> ointment	Therapeutic effect of ointments on aseptic wounds in animals
Group №2 (Control group), n = 10	cats	Vishnevsky liniment	

An experimental study was conducted involving 10 animals, which were divided into two research groups. The first group was treated with a 10% ointment prepared based on the *Artemisia lerchiana* plant, while the second group received treatment using the traditional method – Vishnevsky liniment. The course of treatment was monitored over a period of 10 days. The therapeutic effectiveness in cases of

aseptic wounds was evaluated based on clinical and hematological indicators. Blood samples were collected on days 1, 7, and 10 of the study.

The clinical condition of the animals was assessed using standard veterinary medical methods: attention was paid to the animal's general state, skin condition (integrity, color), and the condition of visible mucous membranes (color, integrity, moisture). Body temperature, pulse rate, and respiration rate were also measured. All of the above-mentioned studies were conducted on the same days as biological sample collection.

When assessing wound healing, special attention was given to the animal's pain response during palpation of the wound edges and surrounding area, manifested by signs of discomfort and vocal reactions. The degree of wound opening in linear skin lesions, inflammation of surrounding tissues, and the moisture level of the wound surface were visually assessed. During the study, the activity of the granulation process and the regenerative capacity of the tissues under ointment treatment were evaluated.

Blood parameters such as hemoglobin level, erythrocytes, leukocytes, platelets, thrombocrit, and hematocrit concentrations were determined. The morphological blood indicators were analyzed using an automated hematology analyzer.

Experimental animals were anesthetized according to the following protocol: xylazine was administered at a dose of 0.15 ml per 1 kg of body weight. Local infiltration anesthesia was performed using a 0.25% novocaine solution. The onset of anesthesia was confirmed by the absence of the corneal reflex and response to painful stimuli.

After collecting the anamnesis and conducting a preoperative clinical examination, the animals were prepared for surgical intervention. Prior to surgery, the cat's bladder was emptied to avoid cranial displacement of the bladder trigone, which increases the risk of accidental ligation of the ureter. A full bladder may also hinder access to the uterine body.

Surgical access was performed along the linea alba, as this technique provides optimal exposure of internal organs. The incision was made equidistantly in cranial and caudal directions from the midpoint between the umbilicus and the pubic symphysis.

To determine the statistical significance of the data, Student's *t*-test was applied, and calculations were performed using Microsoft Excel (2010) software.

Results and analysis. The clinical description of the aseptic wound healing process was carried out according to the experimental design (Table 1).

The tested ointment sample contained *Artemisia lerchiana* essential oil as the active ingredient, with petroleum jelly (vaseline) used as the base (carrier) substance. As a control, a classical postoperative wound treatment regimen was used. Two groups, each consisting of 10 cats, were selected for the experiment based on the principle of analogs. Postoperative treatment and monitoring were conducted over a 10-day period.

For the experimental group, domestic cats were used, and ovariohysterectomy procedures were performed under clinical conditions. All animals underwent preoperative preparation during the 10 days prior to surgery, including treatment against ectoparasites and endoparasites, and were vaccinated against viral diseases such as rhinotracheitis, panleukopenia, and feline calicivirus.

In the control group, postoperative wound treatment was carried out using Vishnevsky liniment.

In the experimental group, a 10% *Artemisia lerchiana* ointment was applied directly to the wound site (Figure 1). Local wound care in both groups was performed twice daily.

On the 3rd day, all animals in the experimental group exhibited a satisfactory general condition. Body temperature remained within the normal range. The postoperative suture area was characterized by moderate severity, with dry wound edges and minimal swelling (Figure 2).

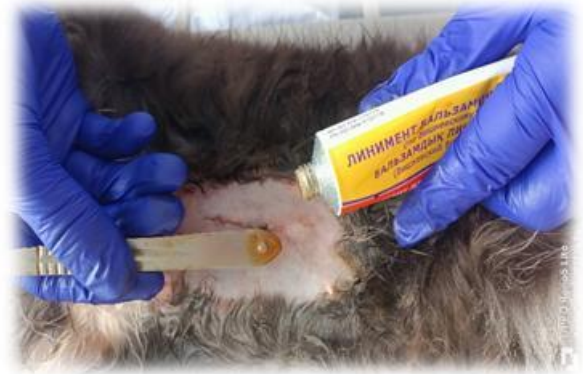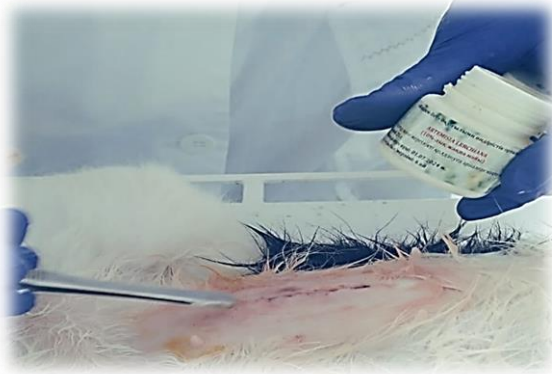

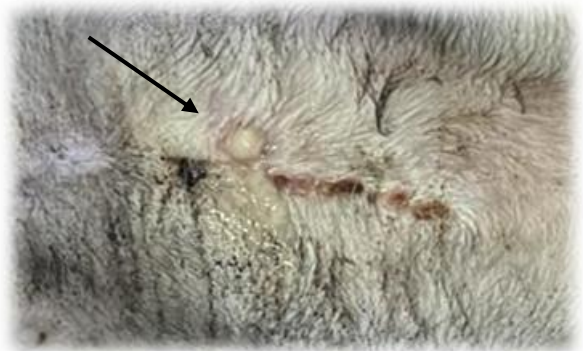
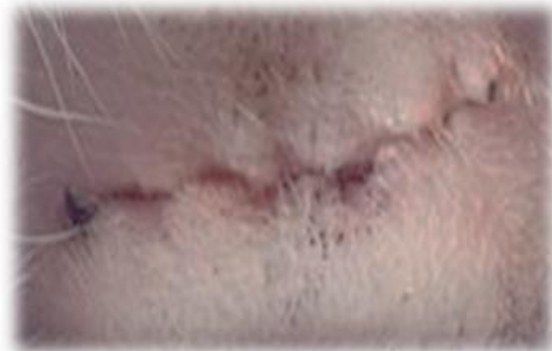Figure 1 – Postoperative wound treatment in the experimental groups (Day 1)



a)

б)

a – 10% *Artemisia lerchiana* ointment; b – treatment with traditional preparation

Figure 2 – Visual appearance of wound healing (Day 3)

Although the overall condition of the control group was satisfactory, two animals exhibited body temperatures above the normal range. The surgical sutures were accompanied by pain, swelling, and the formation of dry wound edges. However, the wound area was also characterized by some moisture along the suture line and a small amount of fluid accumulation on the wound surface.

On day 5, one animal in the control group showed pronounced swelling in the suture area, accumulation of interstitial fluid, pain, elevated local temperature, and a deterioration in general condition. As a result, additional treatment was administered. In the remaining animals, no pathological deviations were observed, and routine monitoring and local treatments were continued.

In the experimental group, monitoring and wound care procedures were also continued. By day 5, postoperative sutures in four animals had begun to heal. The wound edges showed good approximation, and there was no swelling or pain upon palpation of the soft tissues.

By day 7, all animals in the experimental group demonstrated complete wound edge adhesion, absence of pain in the suture area, and clean, dry incision margins. In the control group, the healing process was slower, with the formation of scabs, skin tension, and mild pain observed in the incision area.

In conclusion, the clinical course of postoperative wound healing was found to be more effective with the use of 10% *Artemisia lerchiana* ointment compared to the traditional treatment method. In the experimental group, the wound healing rate was on average 2–3 days faster. Clean wound edges, minimal signs of inflammation, and dryness of the wound surface were more clearly observed in animals from the experimental group.

Along with the healing of the surgical wound, body temperature, heart rate, and respiratory rate were also monitored. The results are described in Figure 3.

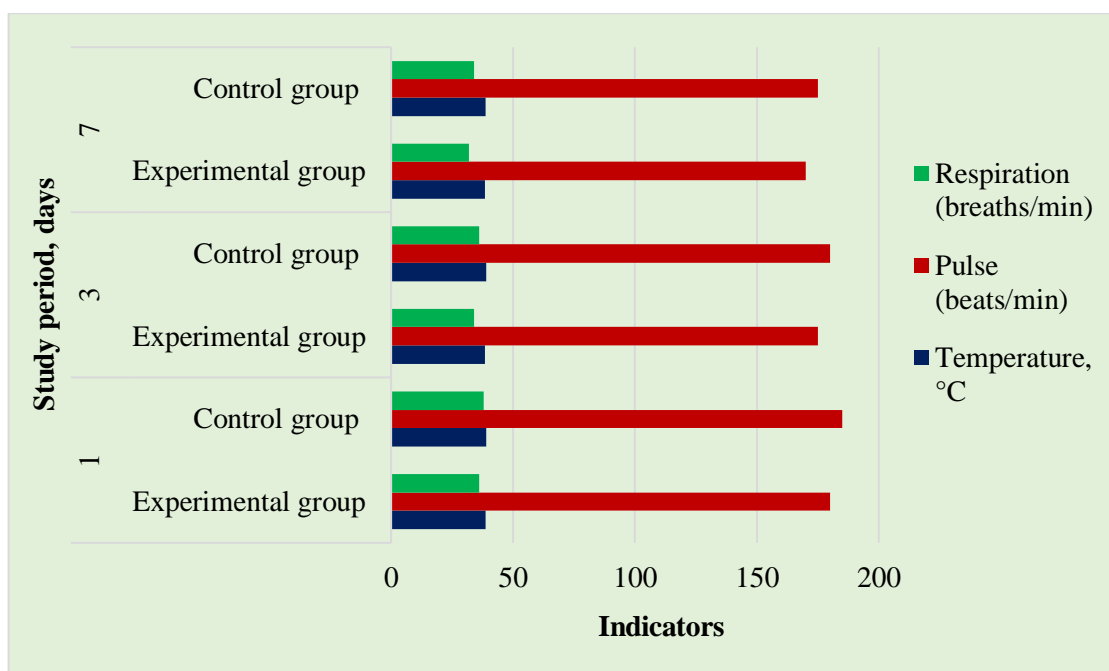


Figure 3 – Dynamics of the body's physiological indicators during the healing process of the surgical wound

Throughout the study, the cats in the experimental group consistently showed lower values of temperature, pulse, and respiration compared to the control group. By day 7, the temperature in the experimental group had decreased to 38.4 °C, while it remained higher in the control group at 38.7 °C. The pulse rate in the experimental group decreased from 180 to 170 beats per minute, whereas in the control group it dropped slightly from 185 to 175 beats per minute. The respiratory rate in the experimental animals also decreased more significantly: from 36 to 32 breaths per minute, compared to 38 to 34 in the control group. This may indicate a positive physiological effect in the experimental group.

Additionally, based on the hematological indicators shown in Table 2, we determined the levels of hemoglobin, erythrocytes and leukocytes, platelets, hematocrit, and thrombocrit concentration.

Table 2 – Morphological composition of feline blood during experimentally induced aseptic wounds

Study period, days	Study groups	Blood parameters					
		Hemoglobin г/л	RBC, 10 ¹² /л	WBC 10 ⁹ /л	Platelet, 10 ⁹ /л	Hematocrit, %	Thrombocrit %
1	2	3	4	5	6	7	8
1	1-Experimental group (10% <i>Artemisia lerchiana</i> ointment)	92,4±0,32	6,6±1,31	8,8±2,33	315,3±2,31	31,2±1,33	0,21±0,61
	2-Control group (Vishnevsky liniment)	95,4±1,23	7,3±2,14	9,1±1,27	435,4±1,37	37,3±2,14	0,18±0,35
7	1-Experimental group (10% <i>Artemisia lerchiana</i> ointment)	89,5±2,21	7,3±1,67	9,3±2,52	327,6±2,14	33,5±1,46	0,25±1,02
	2-Control group (Vishnevsky)	90,1±1,41	7,8±2,11	10,4±2,31	453,4±1,26	35,3±1,63	0,23±0,63

	liniment)						
1	2	3	4	5	6	7	8
10	1-Experimental group (10% <i>Artemisia lerchiana</i> ointment)	95,7±1,16	8,6±1,63	8,9±1,46	321,7±1,33	30,1±1,32	0,24±0,8 1
	2-Control group (Vishnevsky liniment)	93,3±2,33	8,1±1,89	9,7±2,52	437,5±2,15	35,2±1,23	0,25±0,9 1

During the study, on day 1, the hemoglobin level in the experimental group (treated with 10% *Artemisia lerchiana* ointment) was 92,4 g/L, while in the control group it reached 95,4 g/L, which is 3,0 g/L higher. This difference indicated greater erythrocyte activity in the control group at the initial stage. Conversely, by day 10, hemoglobin in the experimental group increased to 95,7 g/L, surpassing the control group (93,3 g/L) by 2.4 g/L, suggesting improved oxygen supply to the tissues during wound healing.

The erythrocyte count on day 1 was $6,6 \times 10^{12}/L$ in the experimental group and $7,3 \times 10^{12}/L$ in the control group. However, by day 10, the experimental group showed an increase to $8,6 \times 10^{12}/L$, which was $0,5 \times 10^{12}/L$ higher than the control group ($8,1 \times 10^{12}/L$), indicating an active regeneration process.

Leukocyte counts were consistently higher in the control group throughout all observation periods. For example, on day 7, the experimental group had $9,3 \times 10^9/L$, while the control group had $10,4 \times 10^9/L$, a difference of $1,1 \times 10^9/L$. These results suggest a mild inflammatory process in the control group.

Platelet counts remained stable in the experimental group ($315,3-327,6-321,7 \times 10^9/L$), whereas the control group exhibited significantly higher levels: $435,4-453,4-437,5 \times 10^9/L$, with a difference of approximately $115-125 \times 10^9/L$ throughout the study. This indicates a more active thrombosis process on the wound surface in the control group.

Hematocrit values on day 10 were 30,1% in the experimental group and 35,2% in the control group, a 5,1% decrease, reflecting blood dilution and active circulation of tissue fluids.

Thrombocrit was slightly higher in the experimental group, especially on day 7, showing 0,25% compared to 0,23% in the control group, a difference of 0,02%, indicating increased platelet activity during wound healing.

Overall, blood recovery parameters in the group treated with *Artemisia lerchiana* ointment remained within physiological limits, while the control group exhibited more pronounced inflammation and coagulation processes. Therefore, the 10% ointment prepared from *Artemisia lerchiana* can be recommended as an effective phytotherapeutic agent for the treatment of aseptic wounds.

Conclusion. The conducted study demonstrated that the use of a 10% ointment based on *Artemisia lerchiana* essential oil significantly improves the healing process of postoperative aseptic wounds in domestic cats compared to the traditional treatment method. The experimental group showed faster wound epithelialization, absence of pronounced inflammation, and minimal swelling around the sutures. Physiological parameters such as body temperature, heart rate, and respiratory rate were more stable and closer to normal in animals treated with the medicinal ointment. Hematological parameters in this group also indicated a more balanced recovery, with fewer signs of inflammation and reduced activity of the blood coagulation system.

In the control group, more pronounced inflammatory reactions, elevated temperature, and tenderness in the wound area were observed, which slowed down the healing process. Increased levels of leukocytes and platelets indicated a more active inflammatory and thrombotic process. Despite this, blood parameters in both groups remained within physiological norms.

Thus, the 10% ointment containing *Artemisia lerchiana* essential oil positively influences tissue regeneration, helps reduce inflammation, and improves the overall physiological response of the body to surgical intervention. The use of this phytotherapeutic agent is recommended as an effective treatment for aseptic postoperative wounds in domestic animals. Further research may focus on studying the mechanisms of action and expanding the range of applications for this preparation.

REFERENCES

- 1 Tigieva, Z.B. Study of the general toxic, local irritating, and anti-inflammatory effects of ointment with phytoextracts [Text] / Z.B. Tigieva // Scientific Proceedings of Belgorod State University. Series: Medicine. Pharmacy. – 2011. – No. 4–2(99). – P. 54-56.
- 2 Mahboubi, M. *Mentha spicata* L. essential oil, phytochemistry and its effectiveness in flatulence [Text] / M. Mahboubi // Journal of Traditional and Complementary Medicine. – 2021. – No. 11. – P. 75-81. <https://doi.org/10.1016/j.jtcme.2017.08.011>
- 3 Belous A.S. Treatment of wounds with extract of transgenic *Kalanchoe* leaves with cecipin P1 (histological study) [Text] / A. B. Shevelev, E. V. Trubnikova, Yu. K. Biryukova et al. // Bulletin of the Russian State Medical University. – 2017. – No. 1. – P. 70-78.
- 4 Bezin, A.N., Complex therapy of surgical sepsis in dogs [Text] / I. A. Volodin // Proceedings of Orenburg State Agrarian University. – 2014. – No. 6 (50). – P. 85-87.
- 5 Andreev, V.A. Medicinal Plants: Textbook. – Moscow: Aquarium, 2016. – 250 p.
- 6 Yin, S. Full veterinary medicine for small domestic animals [Text] /S. Yin//Moscow: Aquarium, 2018. – 230p.
- 7 Veterinary Feldsher / ed. by G. A. Kononova. – St. Petersburg: Lan, 2017. – 125 p.
- 8 Negut, I., Strategies for treating infected wounds [Text] / V.Grumezescu, A. M. Grumezescu // Molecules. – 2018. – Vol. 23, No. 9. – P. 2392. <https://doi.org/10.3390/molecules23092392>
- 9 Koehler, J. Hydrogel dressings for bioactive treatment of acute and chronic wounds [Text] / F.P. Brandl, A.M. Goepferich // European Polymer Journal. – 2018. – Vol. 100. – P. 1-11. <https://doi.org/10.1016/j.eurpolymj.2017.12.046>
- 10 Masson-Meyers, D. S. Experimental models and methods for assessing skin wound healing [Text] /D. S. Masson-Meyers// International Journal of Experimental Pathology. – 2020. – Vol. 101, No. 1–2. – P. 21–37. <https://doi.org/10.1111/iep.12346>
- 11 Kotyuk, L.A. Antimicrobial activity of essential oil plants of the Lamiaceae Lindl. family against *Escherichia coli* [Text] / L. A. Kotyuk // Biological Bulletin of Melitopol State Pedagogical University named after Bogdan Khmelnytsky. – 2016. – Vol. 6, No. 1. – P. 216-236. <https://doi.org/10.15421/201612>
- 12 Pashtetsky, V.S., Use of essential oils in medicine, aromatherapy, and veterinary science [Text] / N. V. Nevkruta // Taurian Bulletin of Agricultural Science. – 2018. – No. 1 (13). – P. 15-38.
- 13 Konovalov, D. A. Biopreparations for active coexistence of individuals of the same species [Text] / A. A. Khamilonov // Pharmacy and Pharmacology. – 2016. – Vol. 4, No. 4. – P. 4-33.
- 14 Szopa, A. Wormwood (*Artemisia absinthium* L.): significance in the history of medicine, recent phytochemical advances, therapeutic, cosmetic and culinary applications [Text] / J. Pajor, P. Klin // Plants. – Vol. 9, No. 9. – P. 1–33. <https://doi.org/10.3390/plants9091063>
- 15 Ahamad, J. Pharmacognostic review of *Artemisia absinthium* [Text] /S. R. Mir, S. A. Amin // International Research Journal of Pharmacy. – Vol. 10. – P. 25-31. <https://doi.org/10.7897/2230-8407.10015>
- 16 Batiha G.E., Biologically active compounds, pharmacological effects and pharmacokinetics of wormwood (*Artemisia absinthium*) [Text] / A. Olatunde, A. El-Mleeh // Antibiotics. – Vol. 9, No. 6. – P. 1–25. <https://doi.org/10.3390/antibiotics9060353>
- 17 Russian Federation Patent No. 2157697. Pharmaceutical compositions based on essential oils obtained from plants for use in medicine and veterinary science [Text] / D. Ninkov. – Published 20.10.2000. [Electronic resource]. Available at: <http://bd.patent.su/2157000-2157999/pat/servlet/servlet825f.html> (accessed: 25.05.2017)
- 18 Frolova, A.V. Essential oils as promising sources for developing antimicrobial agents for local treatment of purulent wounds [Text] / A. V. Frolova // Bulletin of Vitebsk State Medical University. – 2010. – Vol. 9, No. 1. – P. 1-10.
- 19 Ponomareva, E. I., Essential oils on the pharmaceutical market [Text] / A. R. Mavrina, E. O. Votintseva, E. I. Molokhova // Theoretical and Applied Aspects of Modern Science. – 2014. – No. 6-2. – P. 116-120.
- 20 Tsedonova, L. P. Antimicrobial activity of essential oil of *Artemisia lerchiana* Web. ex Stechm., growing in Kalmykia [Text] / L. P. Tsedonova // Expansion of Resources. – 1999. – Vol. 35, No. 4. – P. 58-60.
- 21 Karmaliev, R.S. Report on antimicrobial properties of preparations during the development of complex corrosion inhibitor [Text] / F. Kh. Nurzhanova, B. O. Yerteuova // Science and Education. – 2024. – No. 1-1(74). – P. 28-39.

ТҮЙІН

Осы зерттеуде үй мысықтарында асептикалық операциядан кейінгі жаралардың сауығуын ынталандыруда *Artemisia lerchiana* эфир майы негізіндегі 10% майдың тиімділігі бағаланды. Әр топта он мысықтан тұратын екі топ овариогистерэктомия операциясынан өтті және операциядан кейінгі әртүрлі емдеу әдістерін алды: тәжірибелік топқа *Artemisia lerchiana* жақпа майы қолданылса, бақылау тобына Вишневский линименті қолданып, жараны дәстүрлі өңдеу жүргізілді. 10 күндік бақылау кезеңінде жараның сауығу үдерісі, физиологиялық көрсеткіштер (дене температурасы, жүрек соғу жиілігі, тыныс алу жиілігі) және гематологиялық параметрлер бағаланды. Тәжірибелік топта жаралардың эпителизациясы жылдамырақ жүріп, қабыну төмендеген, ісіну минималды және жалпы физиологиялық тұрақтылық бақылау тобына қарағанда жақсы болды. Гематологиялық талдау қалпына келудің теңестірілген көрсеткіштерін көрсетті, лейкоциттер мен тромбоциттердің саны төмендеп, қабыну және коагуляция белсенділігінің төмендегенін білдірді. Бақылау тобында сауығу баяулап, қабыну реакциясы байқалды.

Нәтижелер *Artemisia lerchiana* негізіндегі 10%-дық жақпа май тіндердің регенерациясын тиімді ынталандырып, қабыну үдерісін реттейтінін көрсетті. Сондықтан бұл фитопрепарат үй мысықтарының асептикалық операциядан кейінгі жараларын емдеуде қауіпсіз әрі тиімді құрал ретінде ұсынылады және ветеринарияда кеңінен қолданылу мүмкіндігі бар.

РЕЗЮМЕ

В данном исследовании оценивалась эффективность 10% мази с эфирным маслом *Artemisia lerchiana* в стимулировании заживления асептических послеоперационных ран у домашних кошек. Две группы по десять кошек каждая прошли процедуру овариогистерэктомии и получили различное послеоперационное лечение: экспериментальная группа получала мазь с *Artemisia lerchiana*, а контрольная группа – классическую обработку ран с использованием линимента Вишневского.

В течение 10-дневного периода наблюдения оценивался процесс заживления ран, физиологические показатели (температура тела, частота сердечных сокращений, частота дыхания) и гематологические параметры. Экспериментальная группа показала более быстрое эпителизирование ран, сниженное воспаление, минимальную отёчность и лучшую общую физиологическую стабильность по сравнению с контрольной группой. Гематологический анализ выявил более сбалансированные показатели восстановления с меньшим количеством лейкоцитов и тромбоцитов, что свидетельствует о снижении воспалительной и свертывающей активности. В контрольной группе отмечалось замедленное заживление, повышенная воспалительная реакция и более выраженные признаки дискомфорта.

Результаты указывают на то, что 10% мазь с *Artemisia lerchiana* эффективно способствует регенерации тканей и модулирует воспалительный процесс. Следовательно, данный фитопрепарат рекомендуется как безопасное и эффективное средство для лечения асептических послеоперационных ран у кошек с потенциалом для широкого применения в ветеринарии.